


RESENTING CLINICAL SIGNS

History: For the past 2-3 years has had episodes of staring, lethargy, and confusion with tongue out. Sat up, coughed, and started wobbling 1-2 weeks ago. Episodes happen every 2-6 months. Grade 2 left-sided murmur. Tracheal collapse. BNP 630.

DATE

6/21/22

ECHOCARDIOGRAPHIC FINDINGS

2D, M-mode, and Doppler study.

PERFORMED BY:

Dr. Brian Barnes

INTERPRETED BY

 Keith Blass, DVM,
 MS, DACVIM
 (Cardiology)

Left atrial size is normal. The mitral valve leaflets are mildly thickened, and a mild jet of eccentric mitral regurgitation is present. Left ventricular dimensions are normal. Left ventricular systolic function is hyperdynamic. The aorta and aortic valve appear normal, though mild aortic insufficiency is present. Right atrial and right ventricular dimensions are normal. The tricuspid valve leaflets are mildly thickened, and a mild jet of tricuspid regurgitation is present. TR velocity does not suggest the presence of pulmonary hypertension. The pulmonary artery and pulmonic valve appear normal, though trace pulmonic insufficiency is present. No pericardial effusion or cardiac masses are seen.

ECG during echo: Sinus arrhythmia

PATIENT

Porsche Sian

 LA - 20.6 mm
 LVIDd - 21.3 mm
 LVIDs - 7.5 mm
 FS - 64%
 RA - 13.4 mm
 LVOT - 1.15 m/s
 RVOT - 0.74 m/s
 TR - 2.57 m/s

SPECIES

Canine

BREED

Pomeranian

ASSESSMENT/RECOMMENDATIONS

Degenerative mitral and tricuspid valve disease

SEX

FS

This examination demonstrates mild regurgitation of blood across Porsche's mitral and tricuspid valves resulting from degenerative valve disease. The hemodynamic effects of each of the regurgitations also appear to be mild, as Porsche does not have secondary dilation of any of her cardiac chambers, and her ventricular systolic function is well-preserved. As such, Porsche's valvular diseases appear to be well-compensated, and they do not appear to be the cause of her episodes.

AGE

12 y

Porsche does have a prominent sinus arrhythmia present, therefore, vasovagal syncope/pre-syncope should be considered as a possible cause of her episodes.

No therapy is recommended at this stage of Porsche's valvular diseases.

WEIGHT

4.65 kg

A Holter/event monitor may be warranted to further evaluate Porsche's episodes. A recheck echocardiogram is recommended in ~6 months.

HOSPITAL NAME

Westview VH

REFERRING VET

Dr. Barnes



DATE

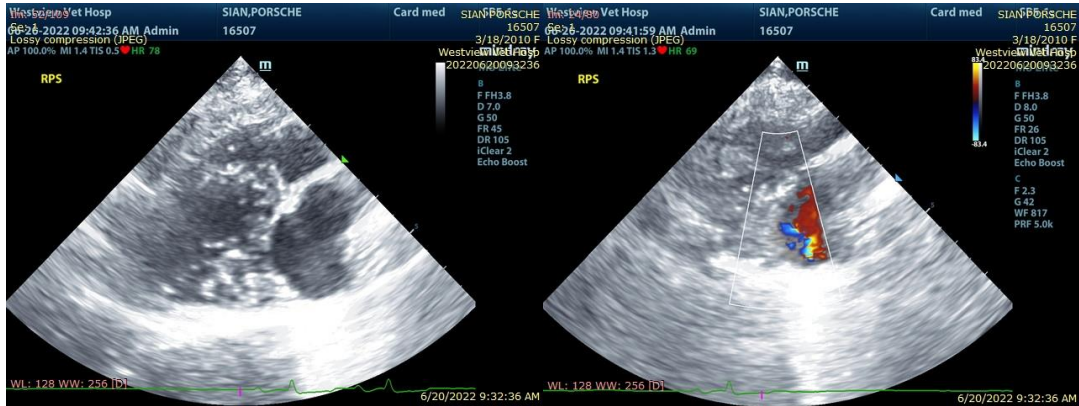
6/21/22

PERFORMED BY:

Dr. Brian Barnes

INTERPRETED BY

Keith Blass, DVM,
MS, DACVIM
(Cardiology)



The information and recommendations provided are based on the images presented by the referring veterinarian. No evaluation can be communicated regarding pathology that was not visible in the image/video clips provided.

PATIENT

Porsche Sian

Thank you for this referral. If the clinical or image interpretation does not parallel your findings or if I can be of any further assistance please contact me.

SPECIES

Canine

Keith Blass, DVM, MS, DACVIM (Cardiology)
KeithBlass@gmail.com
631-804-5754

BREED

Pomeranian

SEX

FS

AGE

12 y

WEIGHT

4.65 kg

HOSPITAL NAME

Westview VH

REFERRING VET

Dr. Barnes